

A CLINICAL STUDY TO EVALUATE OUTCOME OF EXTRA-ARTICULAR FRACTURE DISTAL 1/3RD FEMUR IN ADULTS TREATED BY RETROGRADE NAILING V/S LOCKED COMPRESSION PLATING (LCP)

Parth A. Kansagara¹, Rahil M. Vahora², Pallav S. Mehta³, Mitul K. Patel⁴

Received : 28/04/2023
Received in revised form : 25/05/2023
Accepted : 02/06/2023

Keywords:

Retrograde Nailing, Locked compression plating, Extra-articular distal 1/3rd femur fracture.

Corresponding Author:

Dr. Mitul K. Patel,
Email: mkpatel1294@gmail.com.

DOI: 10.47009/jamp.2023.5.4.240

Source of Support: Nil,
Conflict of Interest: None declared

Int J Acad Med Pharm
2023; 5 (4); 1191-1195



¹Senior Resident, Department of Orthopaedics, GMERS Medical College, Morbi, Gujarat, India.

²Senior Resident, Department of Orthopaedics, GMERS Medical College, Valsad, Gujarat, India.

³Senior Resident, Department of Orthopaedics, PDU Medical College, Rajkot, Gujarat, India.

⁴Assistant Orthopedic Surgeon, Ashutosh Hospital, Vadodara, Gujarat, India. India.

Abstract

Background: To perform detailed comparative study on the outcome of Retrograde nailing v/s Locked compression plating for extra-articular fracture distal 1/3rd femur in adults and evaluation of results. **Materials and Methods:** A retrospective cohort study included 58 patients who received This was a prospective study comprising 23 patients who presented with distal 1/3rd extra-articular femur fractures at C.U. Shah Medical College, Surendranagar from June 2020 to July 2021. They were operated with either retrograde nailing or locked compression plating and their outcome evaluation was done using Knee Society Score. The patients were followed up at 6 weeks, 3 months and 6 months. **Results:** KSS (Knee society score) showed excellent outcomes in 11 and good in 2 patients out of 13 patients of Locked compression plating group and excellent in 9 and poor in 1 patient out of 10 patients of retrograde nailing group. **Conclusion:** In this study both retrograde nailing and locked compression plating gives satisfactory results for management of extra-articular distal 1/3rd femur fractures in terms of range of movements, fracture healing, fewer complications and retrieve to pre-injury occupation. However, a larger scale study with longer follow up is required to evaluate the long-term results.

INTRODUCTION

Distal 3rd femur fracture occurs in two distinct populations, young patients who are victims of high energy trauma and in elderly due to osteoporosis following trivial trauma. Because of severe soft tissue damage, extensive comminution, intraarticular extension and injury to quadriceps mechanism, the management of these fractures present with a significant challenge to orthopedic surgeons.^[1]

Regardless of the method chosen for the management of these fractures, the basic principle is to restore the alignment, rotation and length, preservation of blood supply to aid union, prevent infection and rehabilitation of the affected extremity. In the early 1960s there was great restraint in the surgical treatment of this fracture due to high incidence of infection, non-union, mal-union, inadequate fixation, lack of suitable instruments and implants.^[2] Earlier the treatment options for these fractures were ranging from above knee amputation

to closed reduction with cast application for all reducible fractures.^[2]

After the years, Watson Jones developed the traditional management of displaced Supracondylar femur fracture which included skeletal traction, fracture manipulation and external immobilization in the form of plaster casts applications.^[2] However, these procedures encountered problems such as deformation, shortening, prolonged bed-rest, knee stiffness and instability, joint incongruity, stiffness of quadriceps muscle and post-traumatic osteoarthritis.^[2]

Retrograde nailing and locked compression plating are good and widely accepted choices for management of distal 3rd extraarticular femur fractures but there are very few studies which compare the outcomes of these two methods and thus we have done this study to compare the outcomes between these two methods of fixation.

MATERIALS AND METHODS

The study was conducted in the Orthopedics department of C. U. Shah Medical college and hospital, Surendranagar from June 2020 to July 2021 with minimum 6 months follow up. Total 23 cases were selected which were operated with either retrograde nailing or locked compression plating. Patients were evaluated with regular follow-up x-rays of knee and evaluation of outcome by knee society score.

Inclusion Criteria

- Patients with distal third extra-articular femur fracture.
- Age: 18 years and above
- Patients with 6 months of follow up

Exclusion Criteria

- Pathological fractures of distal third extra-articular femur.
- Distal femur fractures with Neurovascular compromise.
- Patients with other fracture in ipsilateral limb.

On the arrival of patients general and systemic examination of the patients was done followed by ruling out any associated injuries. Then assessment of neurovascular status of limb was done. Then pre-operative investigations and radiological assessment were done and immobilization of injured limb was done.

Surgical Procedure

Locked Compression Plating

Various Approaches are:

- Anterolateral approach
- Posterolateral approach
- Anteromedial approach
- Posterior approach
- Swashbuckler Approach

Locked Compression Plating by MIPO technique by lateral approach

Patient supine on the table with a bolster under the thigh with knee in approximately 30 degrees of flexion. The minimally invasive approach to the distal femur utilizes two windows. Distally, the dissection explores the inter-nervous plane between the vastus lateralis muscle supplied by the femoral nerve and the biceps femoris muscles supplied by the sciatic nerve. Proximally, no internervous plane is available for surgery, but splitting the vastus lateralis muscle usually does not result in significant denervation. Then plate was fixed under image intensifier guidance with proximal and distal screws.

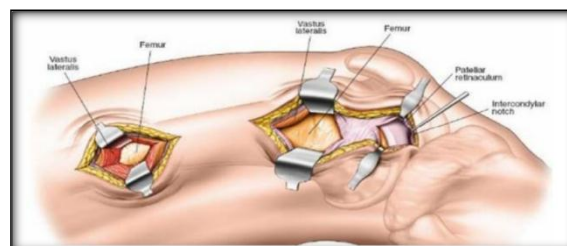
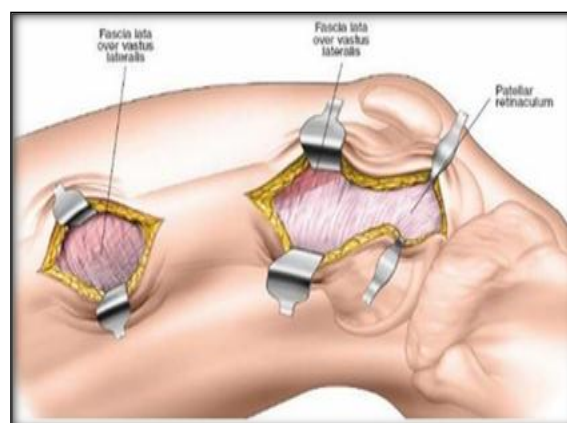


Figure 1: Minimally invasive lateral approach for distal femur

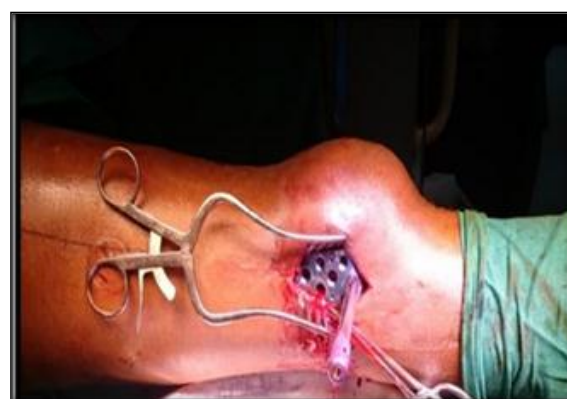

Figure 2: Intra-operative view of plate fixation

Retrograde Nailing

A midline incision was taken from inferior pole of patella up to tibial tuberosity. The paratenon over patellar tendon was sharply incised and the patellar tendon was split in the midline or from the medial border as shown in the figure along the direction of its fibers.

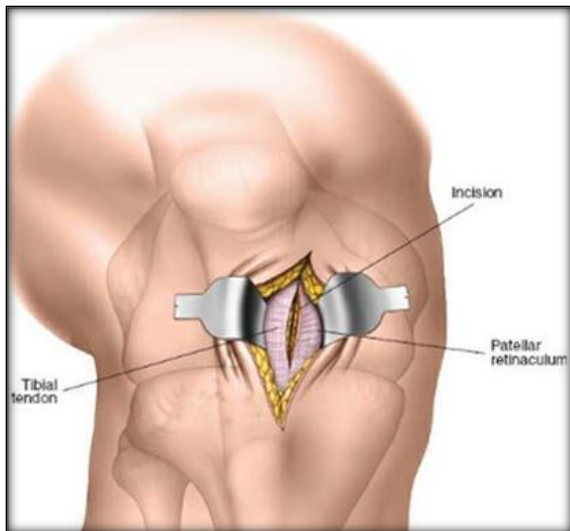


Figure 3: Approach for IMSC nailing

A straight bone awl was inserted into the joint through the split tendon and positioned against the inter-condylar notch. The femoral attachment of Posterior Cruciate Ligament is palpated and the bone awl is kept just anterior to the Posterior Cruciate Ligament attachment.

An entry point was made. The bone awl was then removed and guide wire passed through the entry point while maintaining reduction.

The nail of suitable diameter and sufficient length was then inserted keeping in mind that jig was placed laterally and the convexity of nail facing anteriorly. After taking stab incision over the corresponding lateral skin, drill sleeve was inserted and drilling for proximal bolts was done with help of sleeves by 4.5 mm drill bit. Then 4.9 mm locking bolts one or two of appropriate size were inserted. Similarly, the distal holes were locked in one; two or three numbers using 6.5 mm fully threaded cancellous bolts. The jig was then disengaged, the joint was washed thoroughly to remove the debris, hemostasis achieved and incision closed in layers.

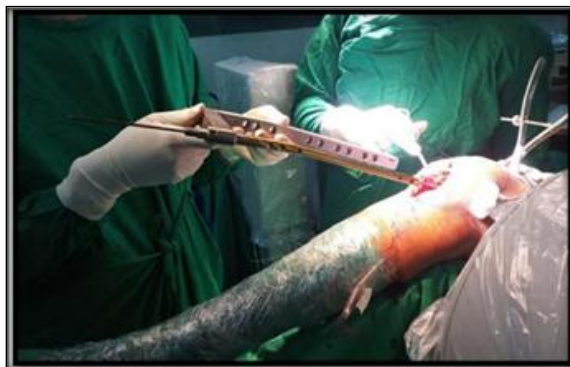

Figure 4: Retrograde Nail Introduced with the help of jig

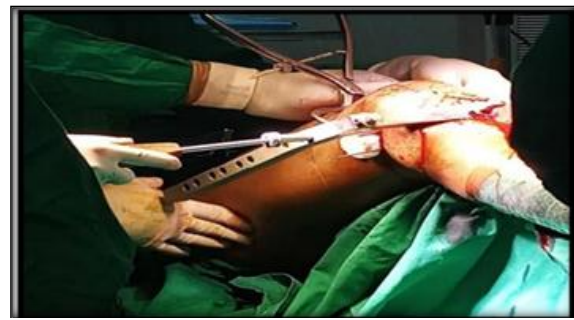

Figure 5: Distal locking of IMSC nail

Postoperative Care

Patient's vitals were monitored. Foot end elevation was given overnight. Antibiotics were given as per the hospital protocol. Analgesics were given as per the patient compliance.

Mobilization

Splints were removed and mobilization of the limb started on the 2nd or 3rd day postoperatively. Mobilization with Non weight bearing was started from the first postoperative week till 4/6 weeks depending on the fracture pattern and then partial weight bearing after confirmation of beginning of healing process till fracture union.

Follow Up

All patients were followed up at 6 weeks, 3 months, and 6 months. During follow up patients were assessed clinically, radiologically and functionally by Knee Society Score.

RESULTS

23 Patients were included in the study among which 13 were operated with locked compression plating and 10 patients with retrograde nailing. This study consisted of 11 male and 12 female patients. Maximum cases were recorded in age group 51-70 with mean age 56 years. Road traffic accident was the most common mode of injury followed by trivial trauma, assault injury and hit by animals. Left side (14 patients) was more commonly involved than right side (9 patients). Non-significant association was observed between age group and mode of injury. Locked compression plating group showed more incidence of stiffness, delayed union and plate impingement whereas retrograde nailing showed more incidence of malunion and nail backout or implant loosening. 10 out of 13 patients retrieved to pre-injury occupation in locked compression plating group whereas 8 out of 10 patients retrieved to pre-injury occupation in retrograde nailing group.

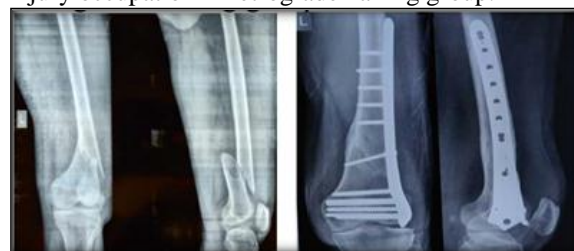

Figure 6: Pre – operative and final follow up x-ray in locked compression plating group

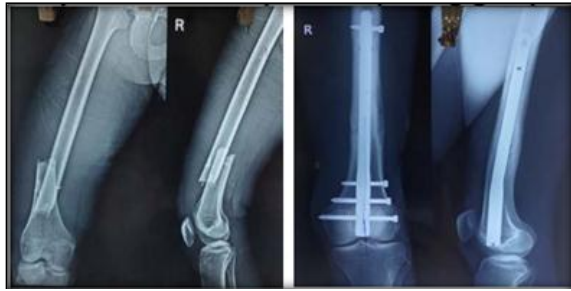

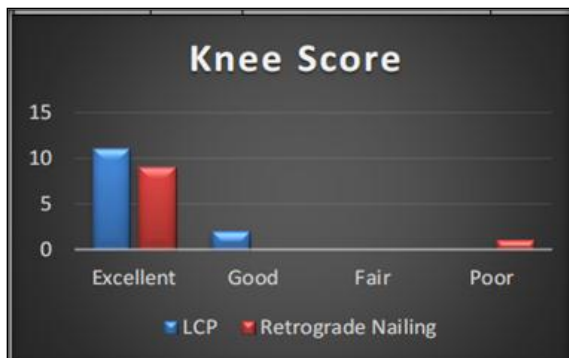Figure 7: Pre – operative and final follow up x-ray in Retrograde Nailing group

Table 1: Distribution of patients by method of management and Knee score of KSS

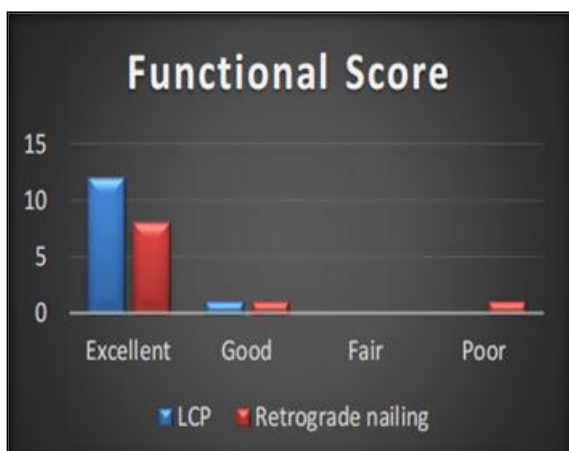Knee score	LCP	Retrograde nailing	Total
Excellent	11	9	20
Good	2	0	2
Fair	0	0	0
Poor	0	1	1
Total	13	10	23

Table 2: Distribution of the patients by method of management and Functional score of KSS

Functional Score	LCP	Retrograde nailing	Total
Excellent	12	8	20
Good	1	1	2
Fair	0	0	0
Poor	0	1	1
Total	13	10	23



Graph 1: Distribution of patients by method of management and Knee score of KSS



Graph 2: Distribution of the patients by method of management and Functional score of KSS

DISCUSSION

Gupta SKV et al.^[3] study had mean age of 47 years whereas our groups mean age was 56 years. Walia JPS et al.^[4] study had 32 males compared to 18 females whereas our study had 11 Males and 12 Females. Similar to above study our study also found major mode of injury to be Road Traffic Accidents. Injury to surgery interval in Rajanish RM et al.^[1] study was 4 days whereas in our study it was 5 days. There were no cases of infection or non-union in our study. There was one case with implant loosening in DFLCP group. There was one case of Retrograde nail backout which led to osteoarthritis of knee and restricted range of motion.

SPS Gill et al.^[5] in his study showed excellent outcomes in 36.36% patients and 40.9% had good outcome, 13.63% fair outcome and 9.09% had poor score according to knee society score (KSS) in locked compression plating group, whereas in IMSC nailing group 45% had excellent score, 35% had good score, 15% had fair score and 5% had poor outcome. In our study 84.61% patients had excellent and 15.39% had good knee score in LCP group whereas 90% patients had excellent and 10% had poor knee score in Retrograde Nailing group.

Limitations of this study

- Limited number of patients that was not large enough to strengthen the significance of the differences.
- Short follow-up period and regular follow up was not available due to COVID 19 pandemic

that was not adequate for obtaining long-term outcomes.

- The operating surgeon was not the same for every surgery.

CONCLUSION

Locked Compression Plating and IMSC nailing could result in satisfactory union and eliminates the need for bone grafting. Proper aseptic precautions and adequate fracture fixation, minimizes risk of infection.

In this study LCP and Retrograde nailing both had similar outcomes for management of extra-articular fractures of distal femur with excellent to good clinical outcomes in term of range of movements, early mobilization, fracture healing, fewer complications, insignificant limb length discrepancy and retrieve to pre-injury occupation.

In case of DFLCP it provides rigid fixation, due to which if reduction is not adequate can lead to delayed or non-union. It also involves larger soft tissue dissection which can lead to large scars than nailing and there can be soft tissue irritation present over the plate due to extramedullary type of implant. Most these complications can be minimized by MIPO technique.

In cases of IMSC nailing there are chances of nail protrusion in joint which can lead to serious complications which can make a patient bedridden.

It can also lead to malunion, and chances of knee joint sepsis are also higher with IMSC nailing, which were not seen in this study, but these can be reduced by proper precautions and fixation.

We have done this study which shows that both DFLCP and IMSC nailing are good choices for fixation of extra-articular type of distal femur fractures, but a detailed and longterm study is needed to compare the outcomes of these two implants and their long-term effects.

REFERENCES

1. Rajanish R Menon, Subramanian V. Functional outcome of distal femoral fractures treated by minimally invasive surgery using locking condylar plate: Kerala Journal of Orthopaedics Volume 27| Issue 1 | January 2014; 22-28.
2. Wilson JN. Watson Jones's: Fractures and joint injuries. 6th ed, pg. 1003070, 1982.
3. SK Venkatesh Gupta, Raju Dande. Surgical management of fracture of distal end of femur in adults by minimal invasive percutaneous plate osteosynthesis (MIPO) with locking condylar plate. IJOS; Mar. 2015; 1(2): 07-11.
4. Walia J.P.S., G Malu, Sonam Kaur Walia, Avinash Chander Gupta, Sudhir Sethi, Sargun Singh. Minimally Invasive Plate Osteosynthesis for Distal Femoral Fractures: JIMSA; Oct-Dec 2014; Vol. 2; 7 No. 4. Pg 197-198.
5. SPS Gill, Ankit Mittal, Manish Raj, Pulkesh Singh, Jasveer Singh and Santosh Kumar. Extra Articular Supracondylar Femur Fractures Managed with Locked Distal Femoral Plate or Supracondylar Nailing: A Comparative Outcome Study. Journal of Clinical and Diagnostic Research. 2017 May, Vol-11(5): 10.7860/JCDR/2017/25062.9936 RC19-RC23. DOI.